


# Calcified and Chondroid Lump or Split

Alireza Khani

Douglass Hanly Moir Pathology



The 48th Annual Scientific Meeting *of the*

Australasian Division of the  
International Academy of Pathology

# Disclosure of Relevant Financial Relationships

---

No relevant financial relationship

# Disclosure of Relevant Financial Relationships

---

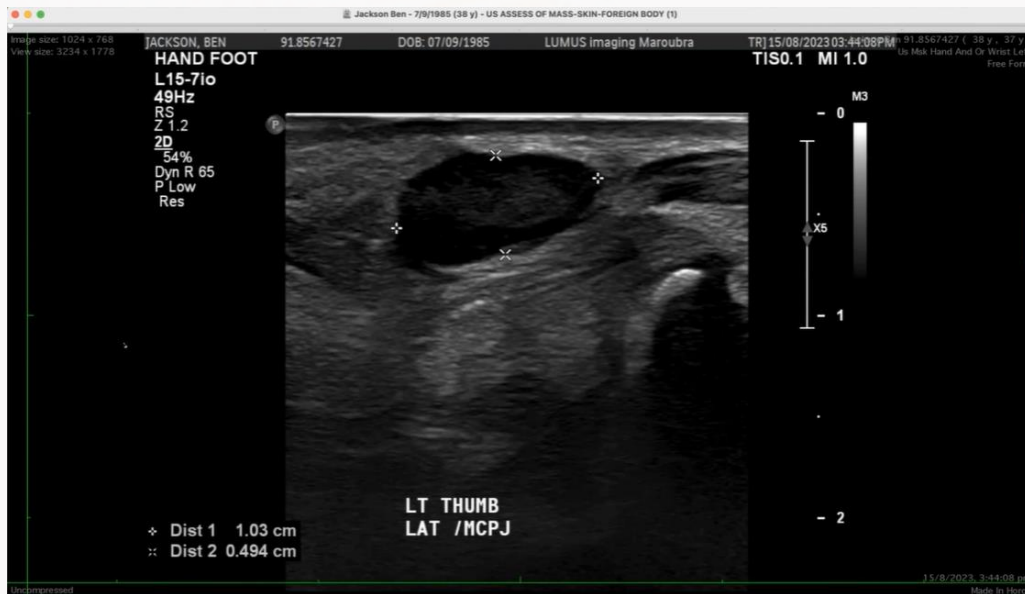# Case

- ❖ 39- year old male referred to orthopaedic surgeon with 2 months history of a lump on his left thumb
- ❖ No past medical history

## Physical examination

- ❖ A firm lump on the ulnar aspect of the left thumb
- ❖ No discolouration
- ❖ MCP joint was not tender to examine and it was stable

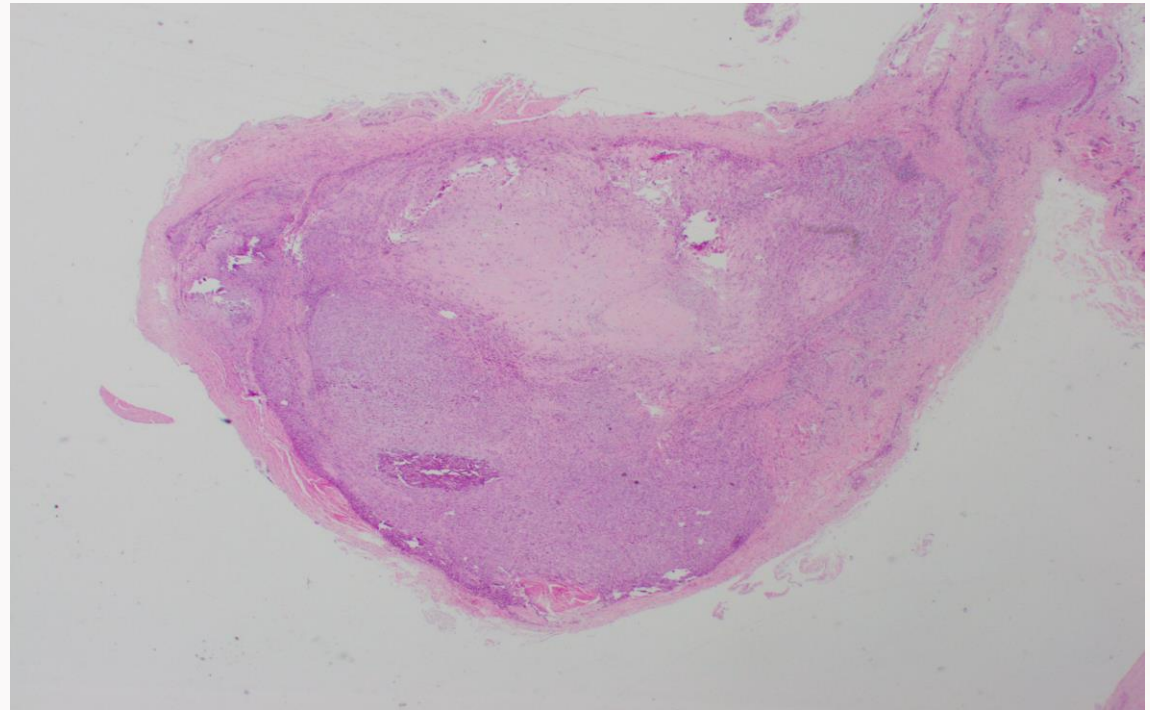
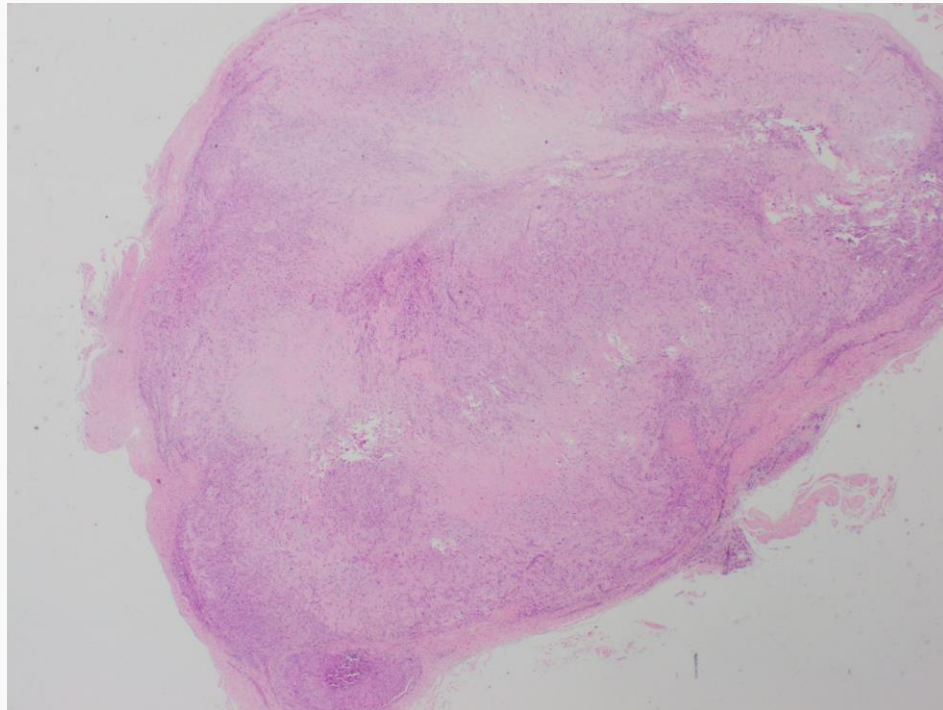
## 12 x 10 mm ovoid hypoechooid nodule with smooth margins

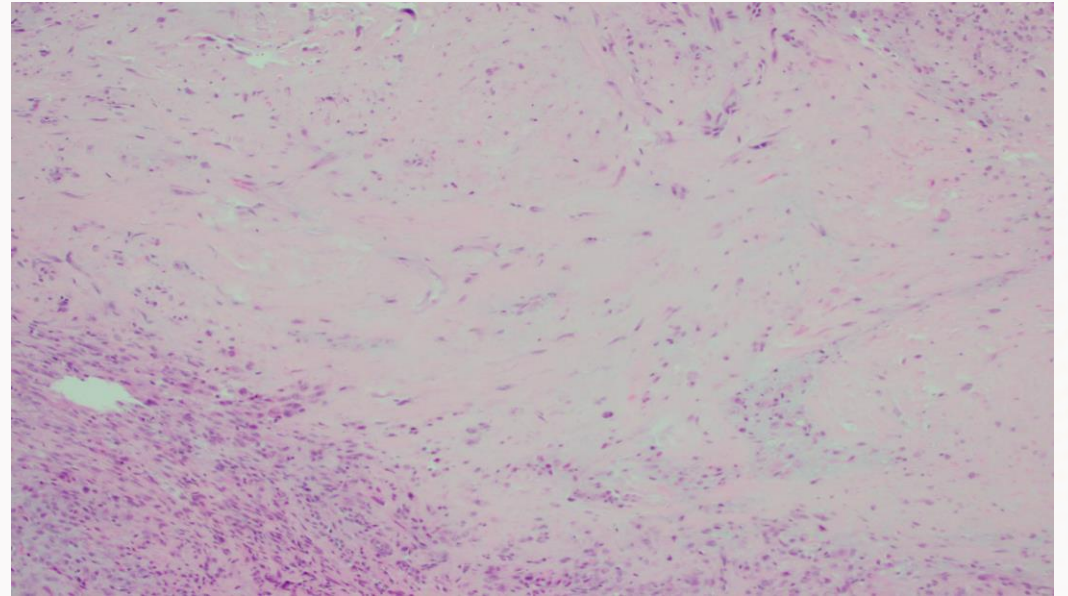
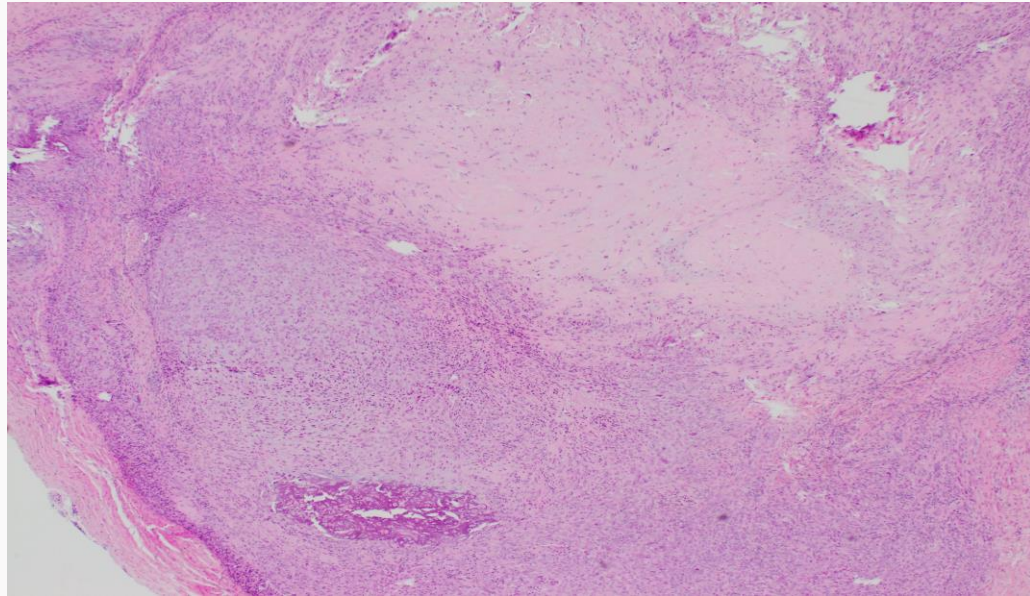


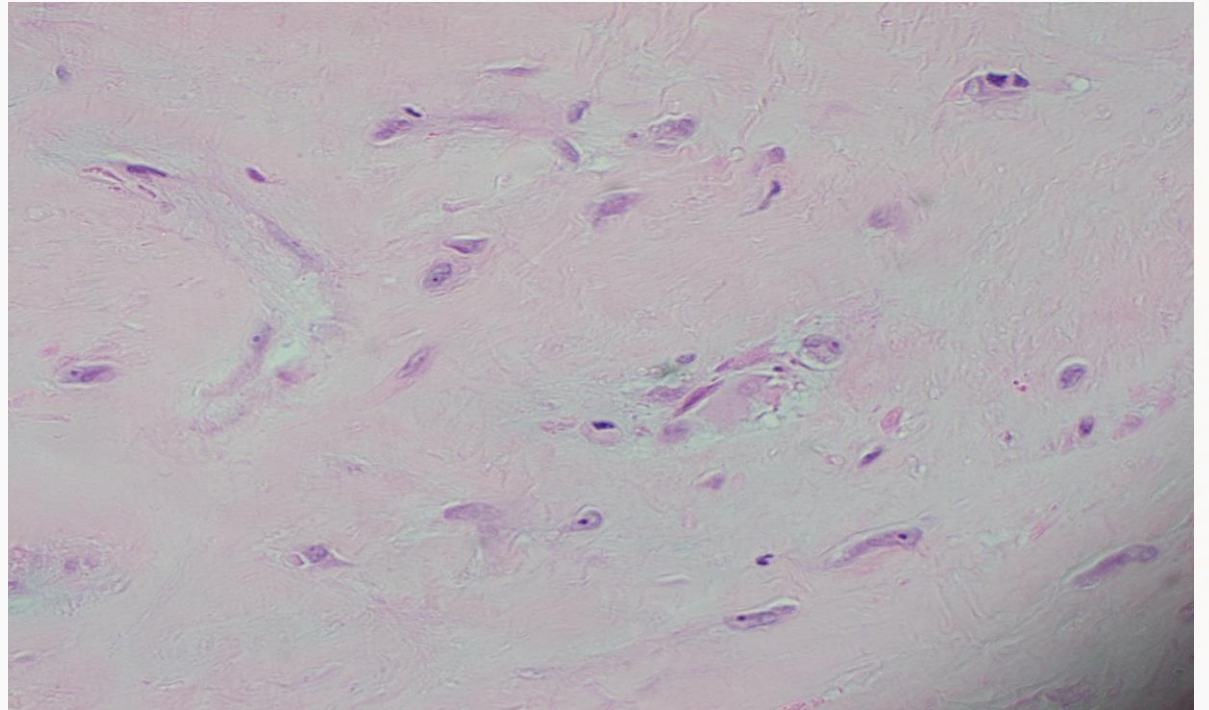
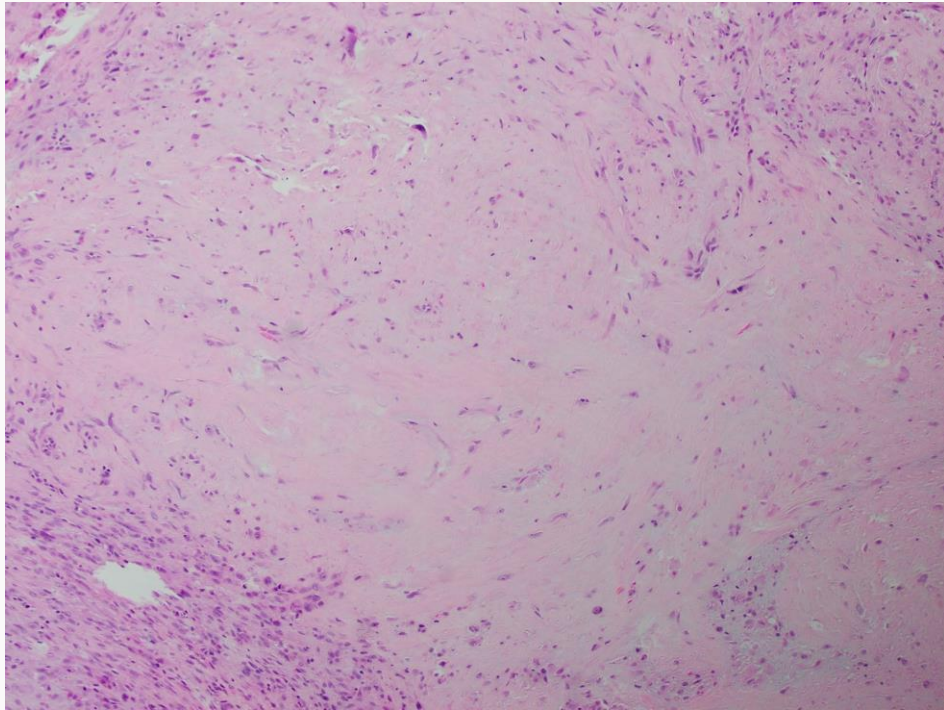
Excisional biopsy

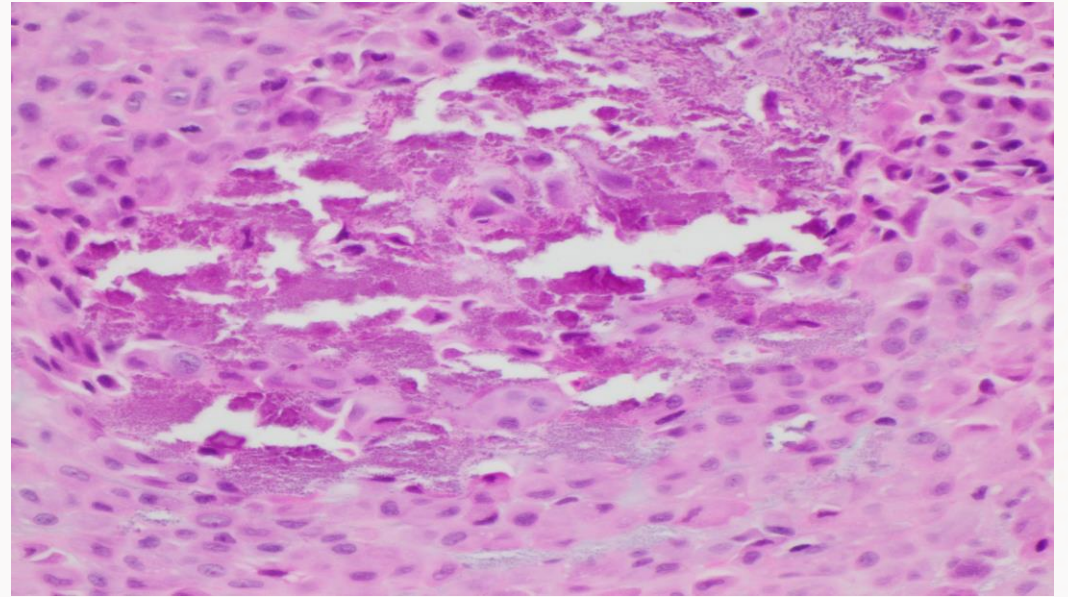
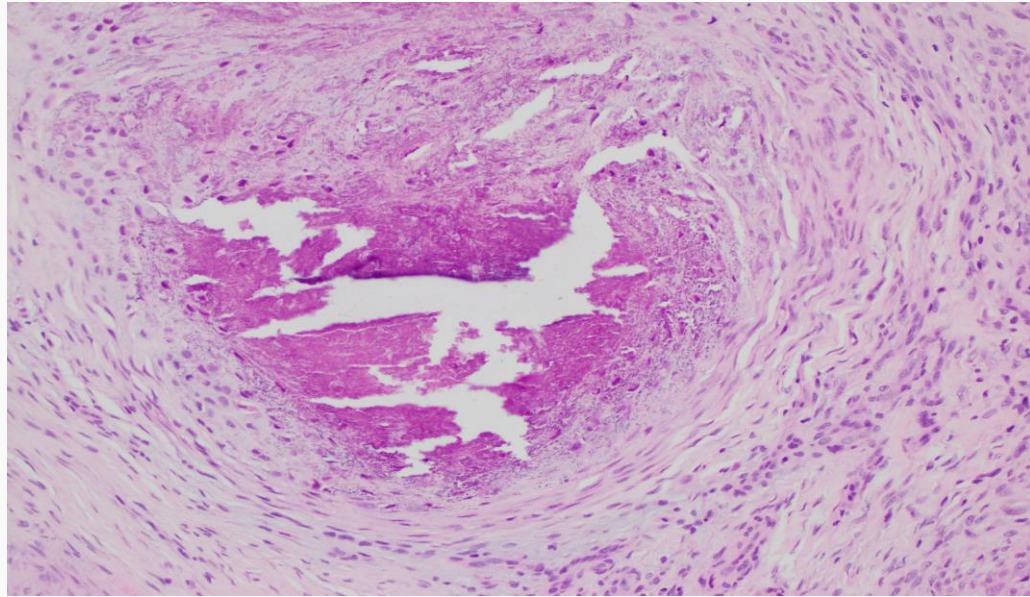
Macroscopy:

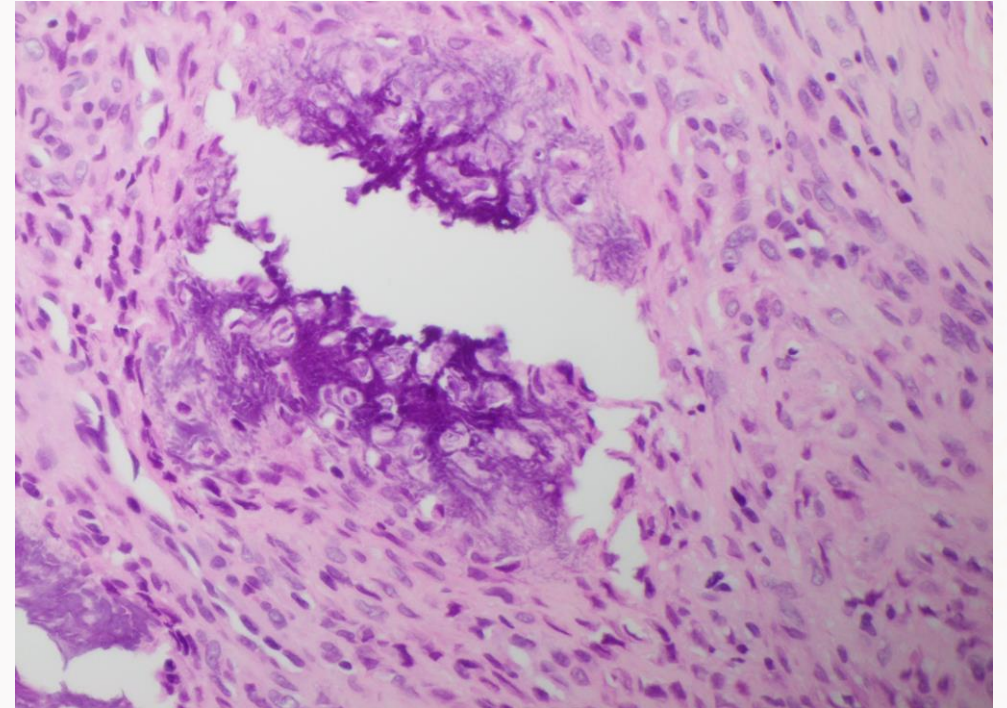
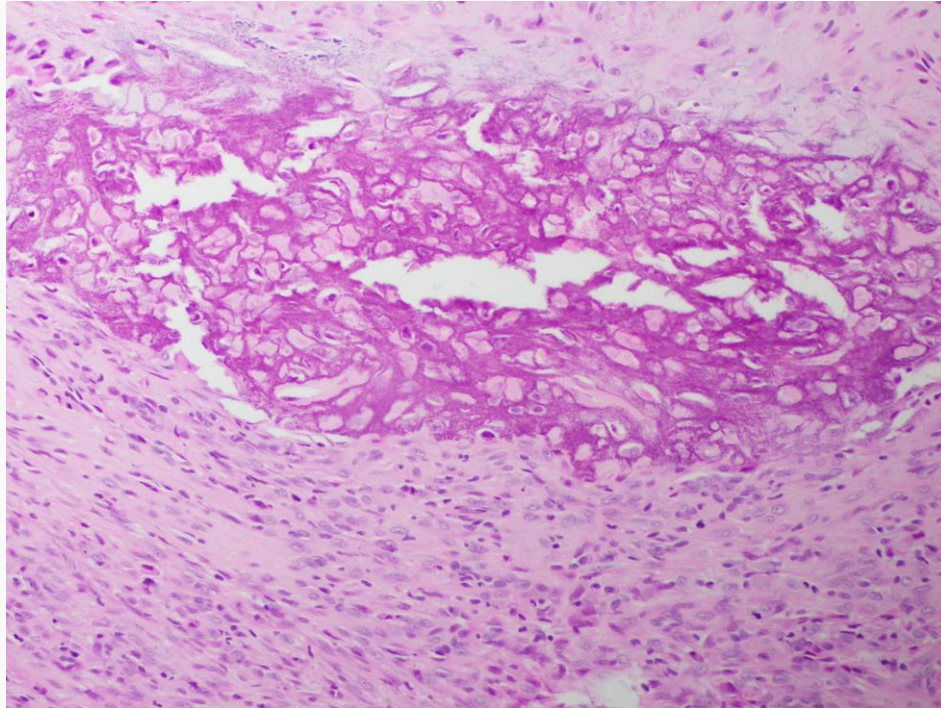
13x9x6mm lesion with tan white cut surface

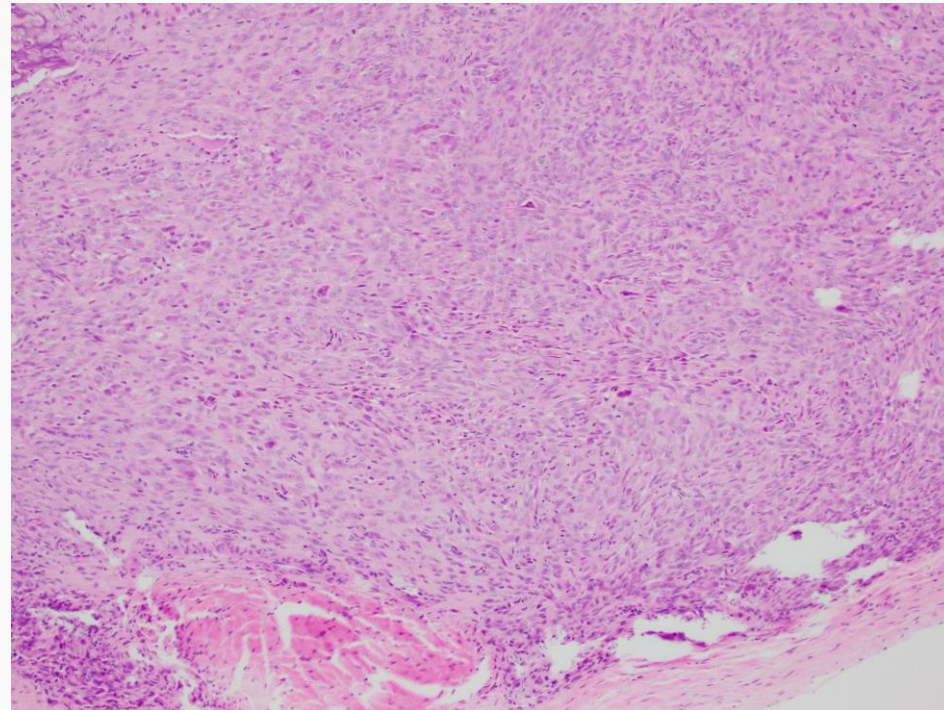


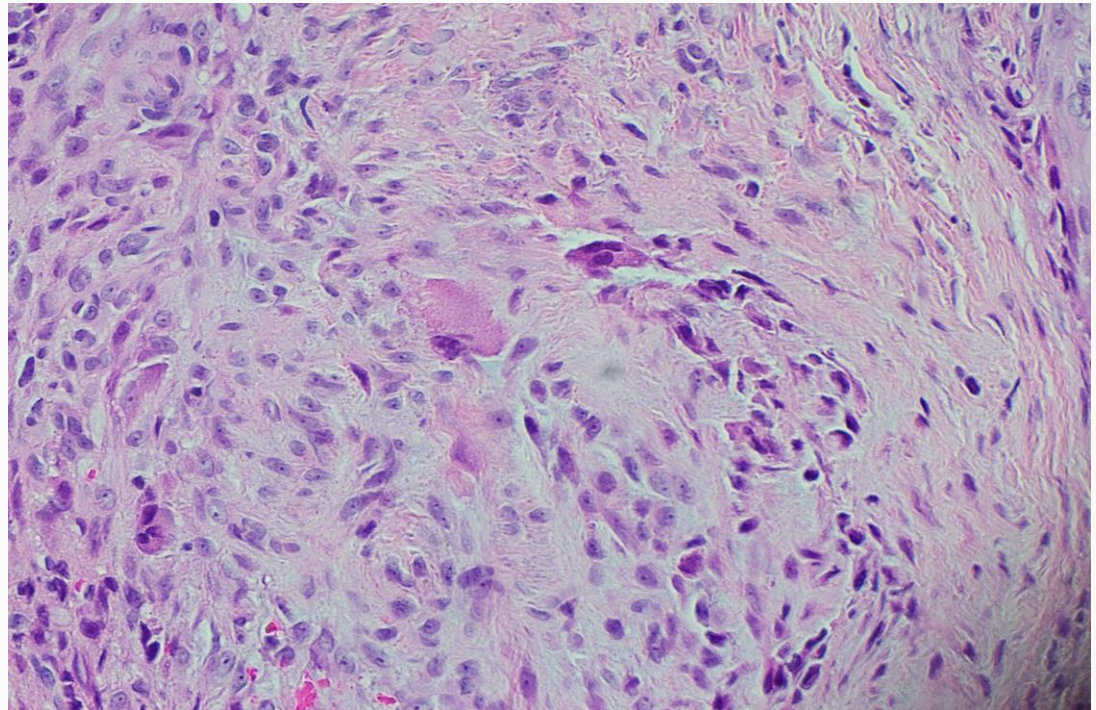
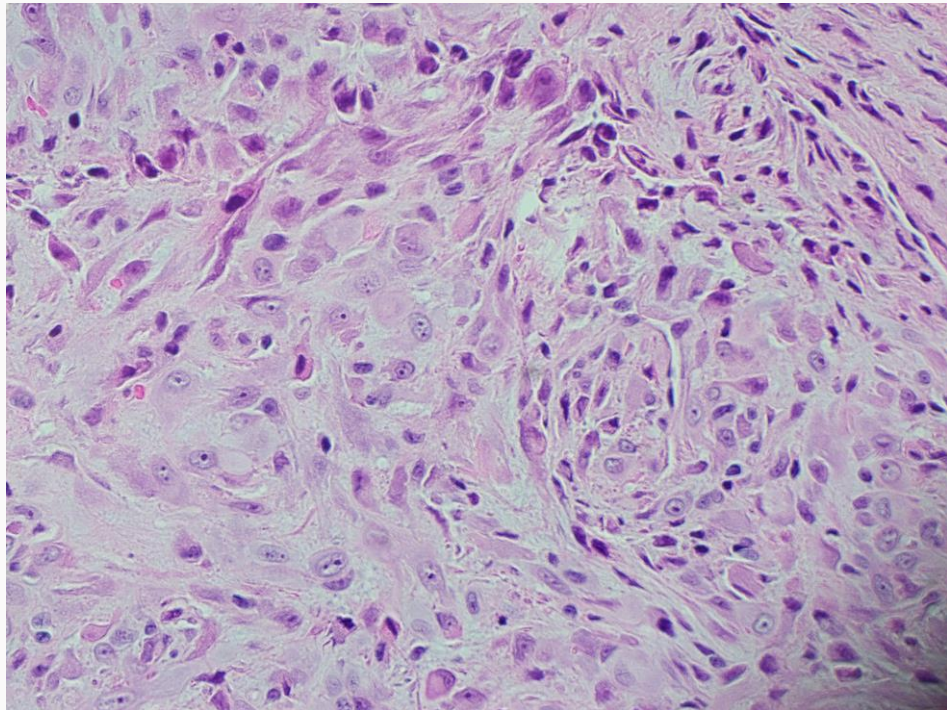


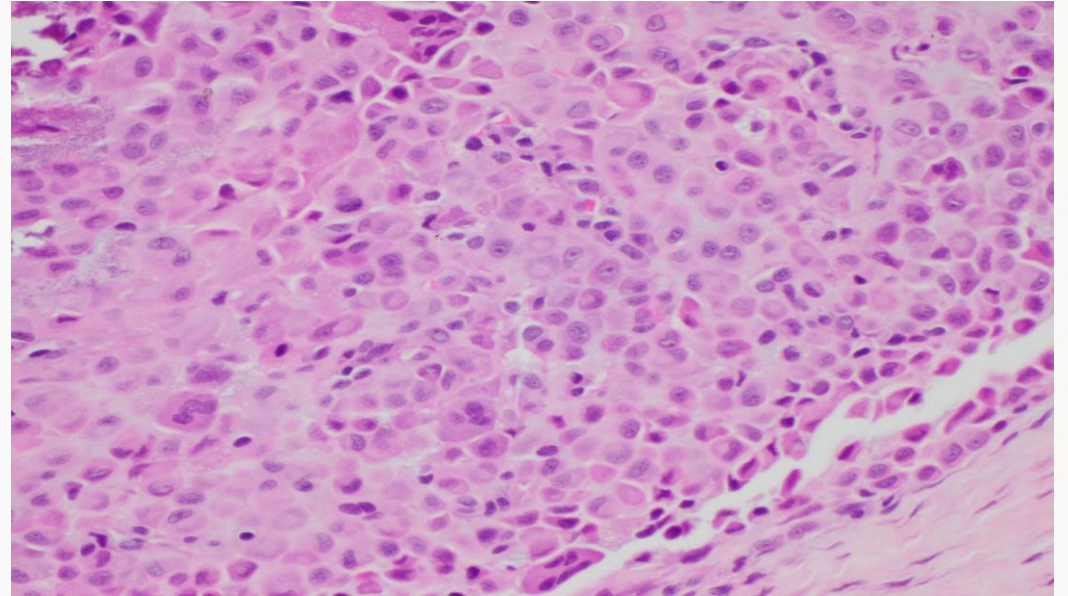
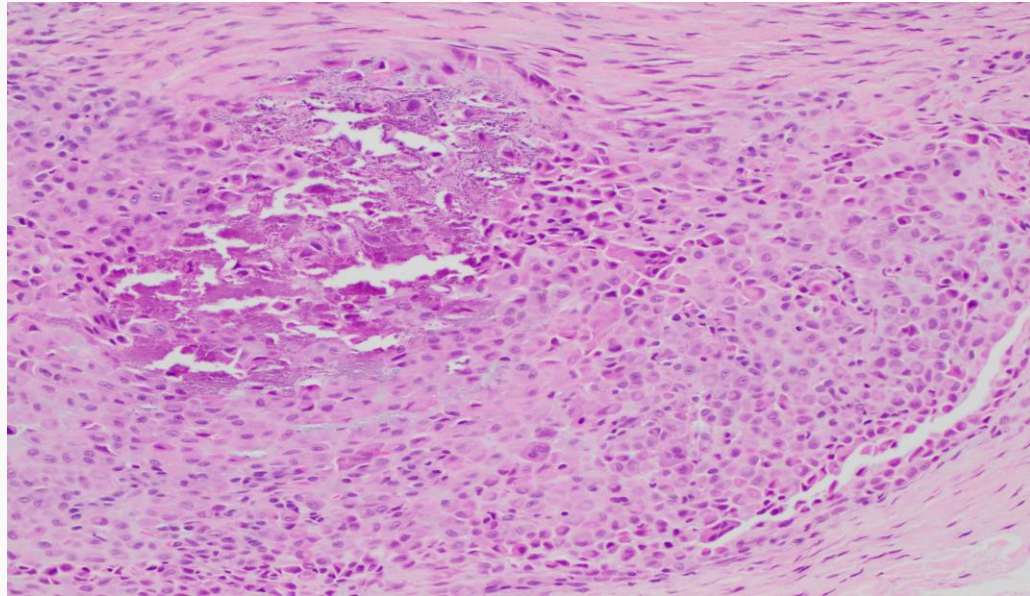


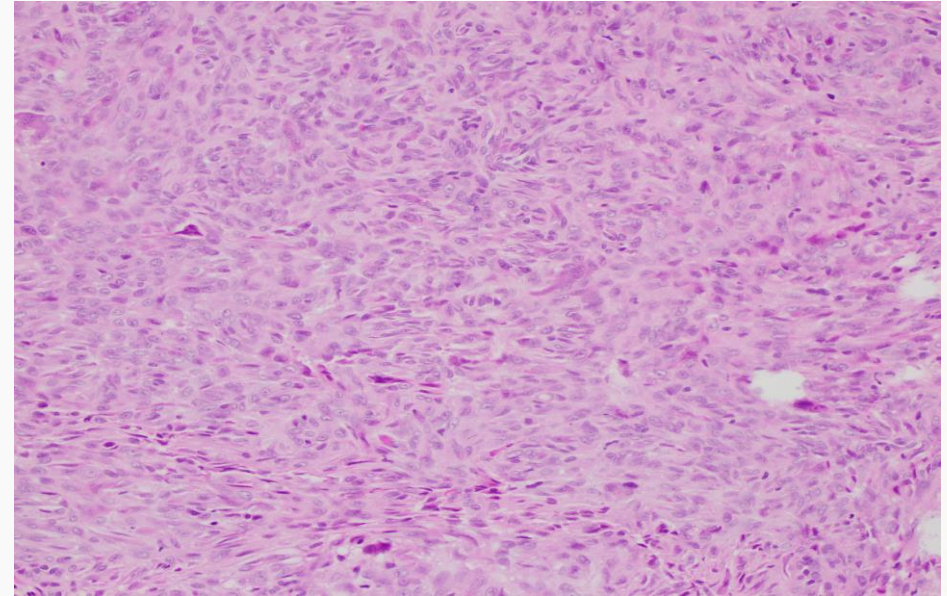
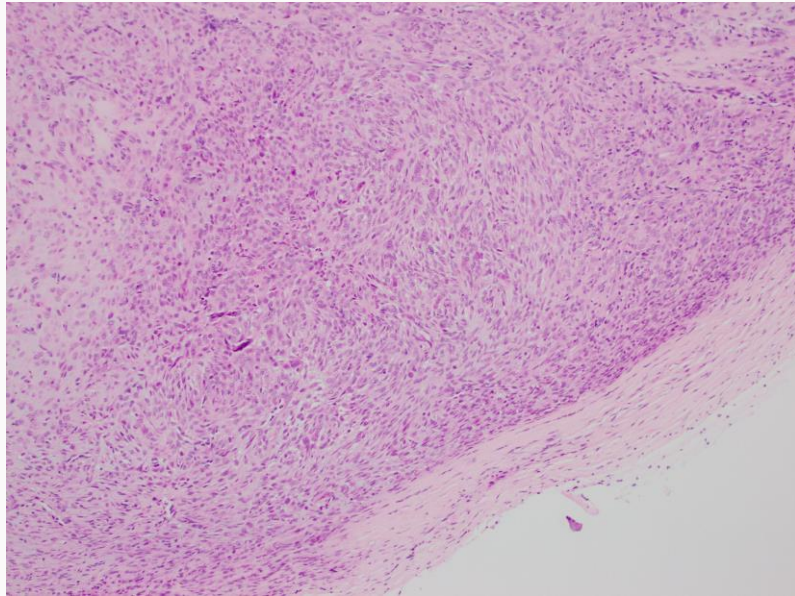












# Differential diagnosis

- ❖ Soft tissue chondroma
- ❖ TGCT
- ❖ Calcifying aponeurotic fibroma
- ❖ Phosphaturic mesenchymal tumour

- ❖ A total of 17 cases of soft-tissue chondroma were retrieved from the authors' consultation files

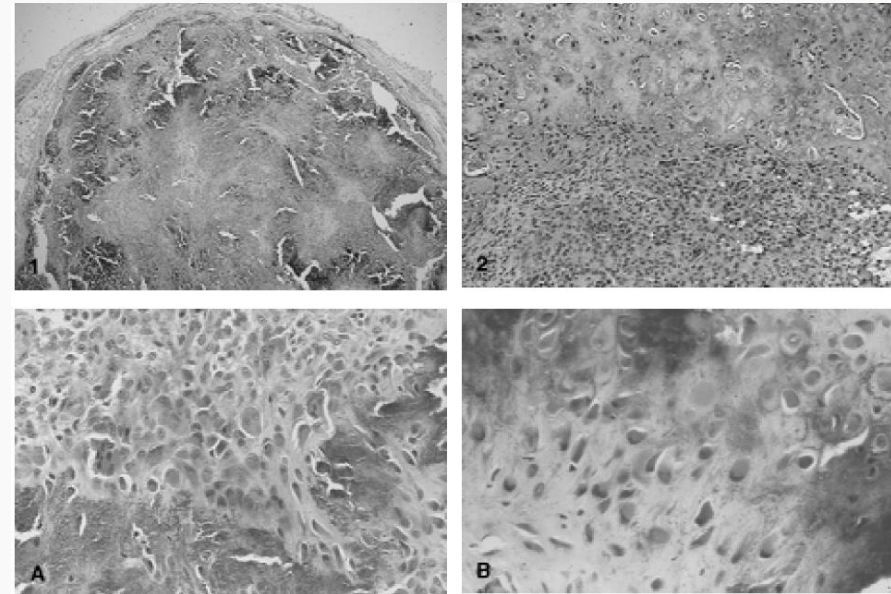
> [Am J Surg Pathol](#). 2001 May;25(5):661-6. doi: 10.1097/00000478-200105000-00015.

### **Chondroblastoma-like chondroma of soft tissue: an underrecognized variant and its differential diagnosis**

J M Cates <sup>1</sup>, A E Rosenberg, J X O'Connell, G P Nielsen



❖ Eight cases (47%) showed areas reminiscent of chondroblastoma of bone

❖ These feature is underrecognized and may cause diagnostic difficulties



Case Report

## Chondroblastoma-like chondroma of soft tissue: report of the first case in the base of skull

[Kirtee Raparia MD<sup>a</sup>](#), [Jerry W. Lin MD, PhD<sup>b</sup>](#), [Donald Donovan MD<sup>b</sup>](#),  
[Jeffrey T. Vrabec MD<sup>b</sup>](#), [Qihui "Jim" Zhai MD<sup>c</sup>](#), [Alberto A. Ayala MD<sup>d</sup>](#),  
[Jae Y. Ro MD, PhD<sup>d</sup>](#)  

Scientific article

## Chondroblastoma-Like Chondroma of the Hand: Case Report

[Tomas K. Kuprys MD](#)  , [Randip Bindra MD](#), [Dariusz Borys MD](#),  
[Lukas M. Nystrom MD](#)

# TMJ region

Modern Pathology (2007) 20, 545–551  
© 2007 USCAP, Inc. All rights reserved 0893-3952/07 \$30.00  
www.modernpathology.org



## Pigmented villonodular synovitis with chondroid metaplasia, resembling chondroblastoma of the bone: a report of three cases

Yoshinao Oda<sup>1</sup>, Teiyu Izumi<sup>1</sup>, Katsumi Harimaya<sup>2</sup>, Yuichi Segawa<sup>1</sup>, Shinichiro Ishihara<sup>3</sup>, Shizuo Komune<sup>4</sup>, Yukihide Iwamoto<sup>2</sup> and Masazumi Tsuneyoshi<sup>1</sup>

Otology/Neurotology

## Tenosynovial giant cell tumors of the temporomandibular joint and lateral skull base: Review of 11 cases

Matthew L. Carlson MD✉, L. Mariel Osetinsky MD, Eran E. Alon MD, Carrie Y. Inwards MD, John I. Lane MD, Eric J. Moore MD

> Int J Surg Pathol. 2011 Apr;19(2):180-7. doi: 10.1177/1066896910381899. Epub 2010 Nov 17.

## Chondroid tenosynovial giant cell tumor: a clinicopathological and immunohistochemical analysis of 5 new cases

Benjamin L Hoch<sup>1</sup>, Roberto A Garcia, Gert J Smalberger

Case Reports > Otol Neurotol. 2013 Aug;34(6):e49-50. doi: 10.1097/MAO.0b013e31827d06f6.

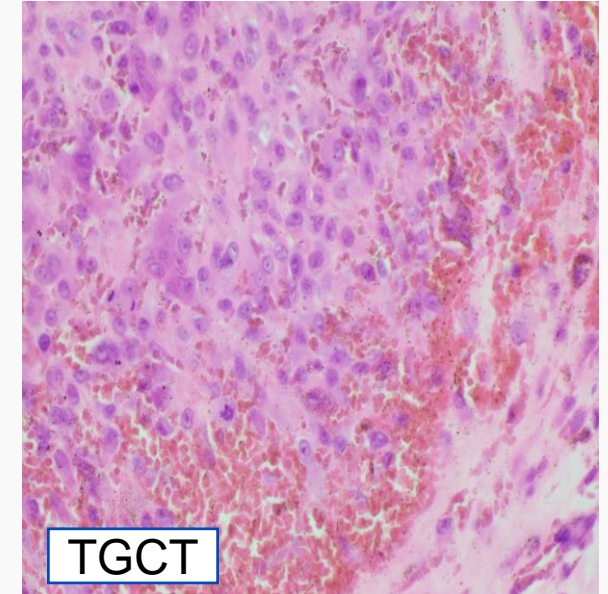
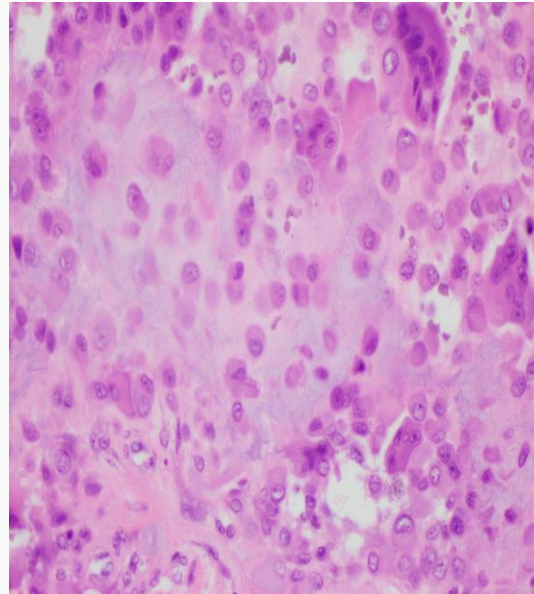
## Chondroid tenosynovial giant cell tumor of the temporal bone

Michelle Fisher<sup>1</sup>, Paul Biddinger, Andrew L Folpe, Brian McKinnon

# TMJ region





Chondroid component similar to the larger mononuclear cells in conventional TGCT, these tumors were thought to represent TGCT with chondroid metaplasia

Often demonstrate locally aggressive growth  
including bone destruction



FN1 gene rearrangement in 50% of their cohort of soft tissue chondromas; notably, all FN1 rearranged tumors exhibited grungy matrix calcification

**Synovial chondromatosis and soft tissue chondroma: extraosseous cartilaginous tumor defined by *FN1* gene rearrangement**

Fernanda Amary <sup>1</sup> · Luis Perez-Casanova<sup>1</sup> · Hongtao Ye<sup>1</sup> · Lucia Cottone<sup>2</sup> · Anna-Christina Strobl<sup>1</sup> · Paul Cool <sup>3</sup> · Elena Miranda<sup>2</sup> · Fitim Berisha<sup>1</sup> · William Aston<sup>1</sup> · Maia Rocha<sup>1,2</sup> · Paul O'Donnell<sup>1</sup> · Nischalan Pillay <sup>1,2</sup> · Roberto Tirabosco<sup>1</sup> · Daniel Baumhoer <sup>4</sup> · Edward S. Hookway<sup>2</sup> · Adrienne M. Flanagan<sup>1,2</sup>

Received: 31 March 2019 / Revised: 4 June 2019 / Accepted: 4 June 2019 / Published online: 4 July 2019  
© The Author(s), under exclusive licence to United States & Canadian Academy of Pathology 2019

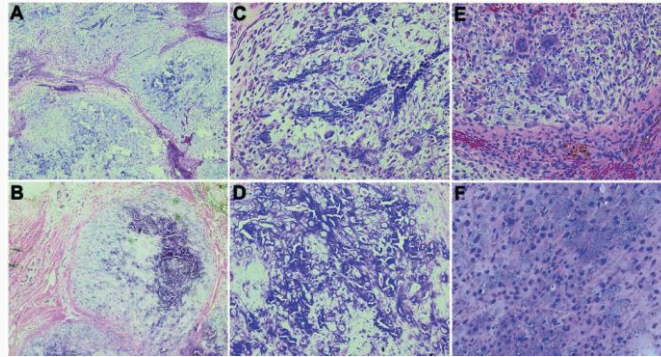
> [J Pathol.](#) 2015 Mar;235(4):539-45. doi: 10.1002/path.4465. Epub 2015 Jan 7.

## Identification of a novel FN1-FGFR1 genetic fusion as a frequent event in phosphaturic mesenchymal tumour

Jen-Chieh Lee <sup>1</sup>, Yung-Ming Jeng, Sheng-Yao Su, Chen-Tu Wu, Keh-Sung Tsai, Cheng-Han Lee, Chung-Yen Lin, Jodi M Carter, Jenq-Wen Huang, Shu-Hwa Chen, Shyang-Rong Shih, Adrián Mariño-Enríquez, Chih-Chi Chen, Andrew L Folpe, Yih-Leong Chang, Cher-Wei Liang

# Calcified chondroid mesenchymal neoplasms

- ❖ Their series described 12 soft tissue tumours with a predilection for the distal extremities and temporomandibular joint
- ❖ FN1 fusion to FGFR1, FGFR2, MERTK, NTRK1, PLAG1 and TEK



Modern Pathology (2021) 34:1373–1383  
<https://doi.org/10.1038/s41379-021-00786-x>



ARTICLE

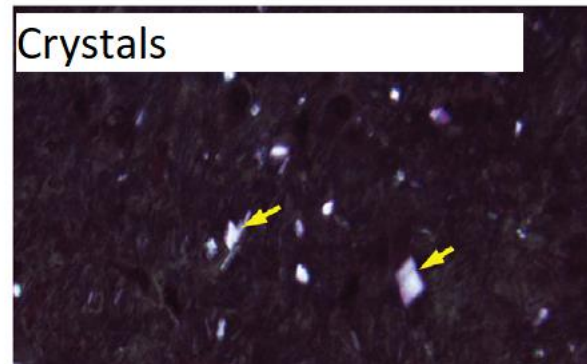
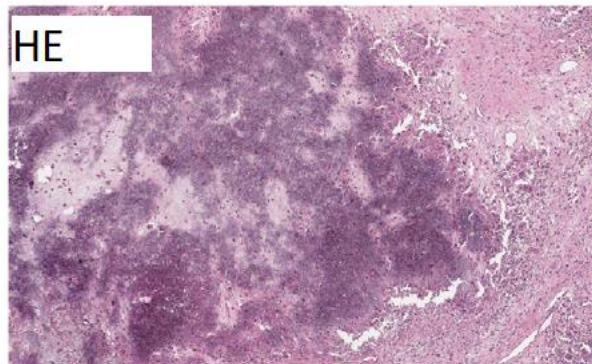


Calcified chondroid mesenchymal neoplasms with *FN1*-receptor tyrosine kinase gene fusions including *FGFR2*, *FGFR1*, *MERTK*, *NTRK1*, and *TEK*: a molecular and clinicopathologic analysis

Yajuan J. Liu<sup>1</sup> · Wenjing Wang<sup>1</sup> · Jeffrey Yeh<sup>2</sup> · Yu Wu<sup>1</sup> · Jose G. Mantilla<sup>1</sup> · Christopher D. M. Fletcher<sup>3</sup> · Robert W. Ricciotti<sup>1</sup> · Eleanor Y. Chen<sup>1</sup>

Received: 18 August 2020 / Revised: 10 February 2021 / Accepted: 13 February 2021 / Published online: 16 March 2021  
© The Author(s), under exclusive licence to United States & Canadian Academy of Pathology 2021

# Heavily mineralization with areas of crystal deposition



## Tophaceous pseudogout of the temporomandibular joint Report of a case

Kenji Kurihara, Kiyoshi Mizuseki, Tadahiko Saiki, Hiroyuki Wakisaka, Shigeo Maruyama, Jur



Case Reports > Int J Oral Maxillofac Surg. 2020 Oct;49(10):1286-1289.

doi: 10.1016/j.ijom.2020.03.011. Epub 2020 Apr 8.

## Tophaceous pseudogout of the temporomandibular joint with erosion into the middle cranial fossa

D Houghton<sup>1</sup>, N Munir<sup>2</sup>, A Triantafyllou<sup>3</sup>, A Begley<sup>4</sup>


Affiliations + expand

PMID: 32278623 DOI: 10.1016/j.ijom.2020.03.011





# Emerging landscape of FN1-rearranged cartilaginous neoplasms

A case of *FN1*-fused calcified chondroid mesenchymal neoplasm of the hand with novel *FGFR3* partner gene

Natalia Georgantzoglou<sup>1</sup>  | Guomiao Shen<sup>2</sup>

Superficial acral calcified chondroid mesenchymal neoplasm harboring an *FN1::FGFR2* fusion and review of the literature

Isidro Machado MD, PhD<sup>1,2,3</sup>  | Vasileia Damaskou MD<sup>4</sup> |  
Eleftherios Ioannidis BSc, MBBS, PhD<sup>5</sup> | George Jour MD<sup>6</sup> | Konstantinos Linos MD<sup>7</sup> 

## Proposed diagnosis

- ❖ Soft tissue chondroma (4 cases)
- ❖ Phosphaturic mesenchymal tumour (3 cases)
- ❖ Tenosynovial giant cell tumour with metaplastic cartilage (1 case)
- ❖ Ossifying fibromyxoid tumour (1 case)
- ❖ Bizarre parosteal osteochondromatous proliferation (1 case)
- ❖ Chondroblastoma (1 case)
- ❖ Sarcoma or chondrosarcoma variant (4 cases)

ORIGINAL ARTICLE

### Calcified Chondroid Mesenchymal Neoplasm

*Exploring the Morphologic and Clinical Features of an Emergent Entity  
With a Series of 33 Cases*

*Michael E. Kallen, MD,\* Michael Michal, MD, PhD,† Anders Meyer, MD,‡ David I. Suster, MD,§  
Nicholas J. Olson, MD,||¶ Gregory W. Charville, MD, PhD,# Raul Perret, MD, MSc,\*\*  
and John M. Gross, MD, MS††*

# IHC

The immunophenotype is not specific and generally not helpful in the diagnosis

Positive: S100 protein (2/12 cases), desmin (1/6 cases), CD68 (1/2 cases), CD34 (1/7 cases), CD56 (1/3 cases), SATB2 (2/3 cases), and SSTR2A(2/2 cases)

# Prognosis

- ❖ Limited follow-up data available
- ❖ Recurrences do occur after complete or incomplete surgical excision, but seem to be infrequent
- ❖ It is not clear if all of these cases represent complete or incomplete surgical excisions

# Prognosis

The American Journal of Surgical Pathology 25(5): 661-666, 2001

© 2001 Lippincott Williams & Wilkins, Inc., Philadelphia

## Chondroblastoma-Like Chondroma of Soft Tissue

An Underrecognized Variant and Its Differential Diagnosis

Justin M. Cates, M.D., Ph.D., Andrew E. Rosenberg, M.D.,  
John X. O'Connell, M.B., B.Ch., F.R.C.P.C., and G. Petur Nielsen, M.D.

Recurrence: 1/6  
(%17)

> Int J Surg Pathol. 2011 Apr;19(2):180-7. doi: 10.1177/1066896910381899. Epub 2010 Nov 17.

## Chondroid tenosynovial giant cell tumor: a clinicopathological and immunohistochemical analysis of 5 new cases

Benjamin L Hoch<sup>1</sup>, Roberto A Garcia, Gert J Smalberger

Recurrence: 1/5  
(%20)

## 39- year old male with left thumb lesion

Positive: Focal positivity with SATb2, S100 and SSR2A

Negative: SMA, desmin, FGF23, CD57, S100, FGF23, Pan CK, ERG, CD34, CD31

# 39- year old male with left thumb lesion

RNA NGS

# Solid Tumour RNA Report (507 genes)

A fusion transcript of potential clinical significance, **PDGFRA::USP8 fusion transcript**, has been identified.

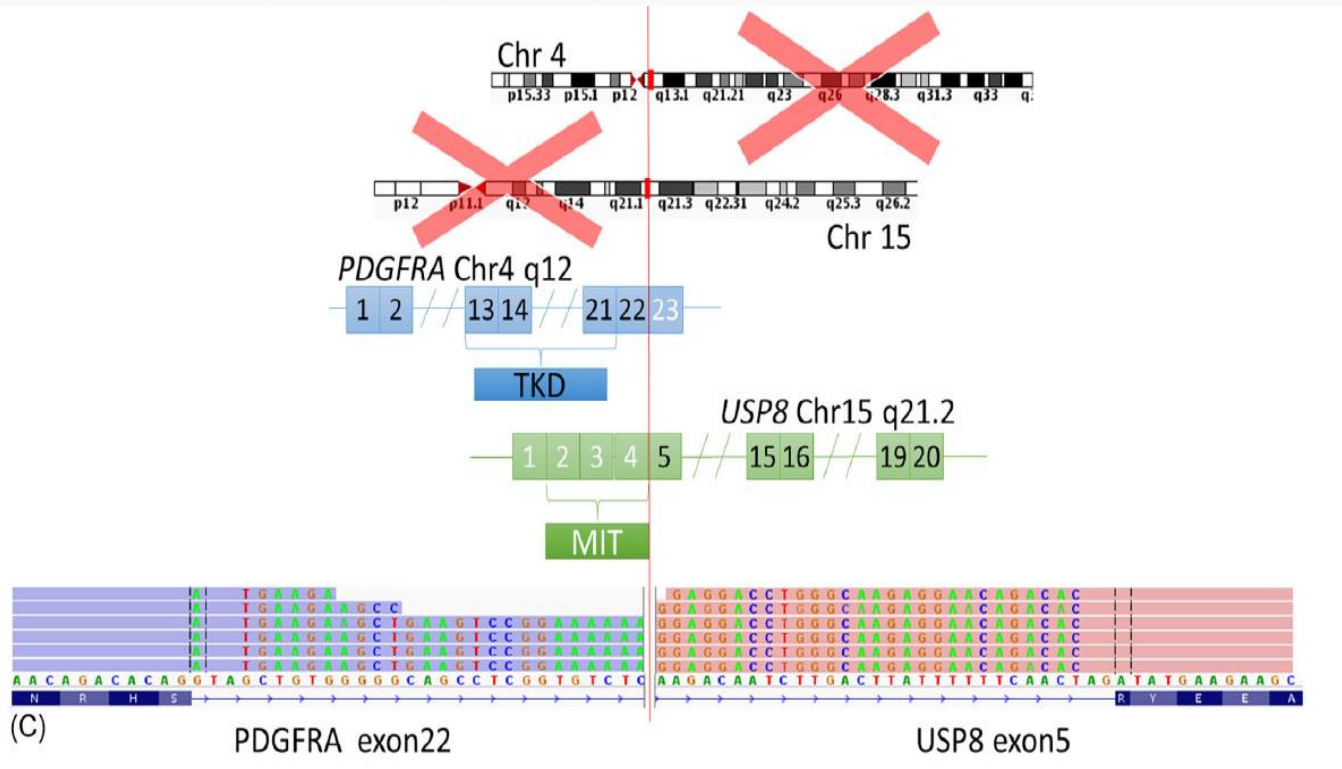
*Please note that these results should be read strictly in conjunction with the histopathological findings and not in isolation. The final report will be issued by the anatomical pathologist after assessing these results.*

## Genomic Findings

IA	IB	IIC	IID	
No variants reported.	No variants reported.	No variants reported.	<b>PDGFRA, USP8</b>	<i>PDGFRA- USP8 fusion transcript</i>
			0 Clinical Trials	

### CLINICALLY RELEVANT RESULTS

## Tier I - Strong Clinical Significance



Received: 26 April 2023 | Revised: 25 July 2023 | Accepted: 12 August 2023

DOI: 10.1002/gcc.23197

RESEARCH ARTICLE

WILEY

## Expanding the spectrum of tyrosine kinase fusions in calcified chondroid mesenchymal neoplasms: Identification of a novel PDGFRA::USP8 gene fusion

Yael Fisher<sup>1</sup> | Maribel D. Lacabra<sup>2</sup> | Shahd S. Almohsen<sup>1</sup> | Chit Chow<sup>2</sup> | Jason L. Hornick<sup>3</sup> | Ka-Fai To<sup>2</sup> | Brendan C. Dickson<sup>1</sup>

# Discussion

- ❖ Genetic diversity
- ❖ They appear to be united in their pathogenesis through protein kinase activation

- ❖ 18 cases of chondroid tenosynovial giant cell tumour
- ❖ The lesional cells are synoviocytes in nature
- ❖ Expressing Clusterin

### **Chondroid Tenosynovial Giant Cell Tumor: A Clinicopathologic, Immunohistochemical and Molecular Genetic Study of a Distinct Synoviocytic Neoplasm**

Erica Y. Kao<sup>1</sup> MD, Fisun Ardic<sup>2</sup> MD, Numrah Fadra MS<sup>3</sup>, Jessie Hohenstein PhD<sup>3</sup>, Rohini Mopuri MS<sup>3</sup>, Doris E. Wenger MD<sup>4</sup>, Lukas Streich MD<sup>5</sup>, and Andrew L. Folpe MD<sup>6</sup>

Despite production of unusual calcified matrix and harbouring FN1 morphologic and immunohistochemical features of C-TGCT are identical to conventional TGCT

## **Chondroid Tenosynovial Giant Cell Tumor: A Clinicopathologic, Immunohistochemical and Molecular Genetic Study of a Distinct Synoviocytic Neoplasm**

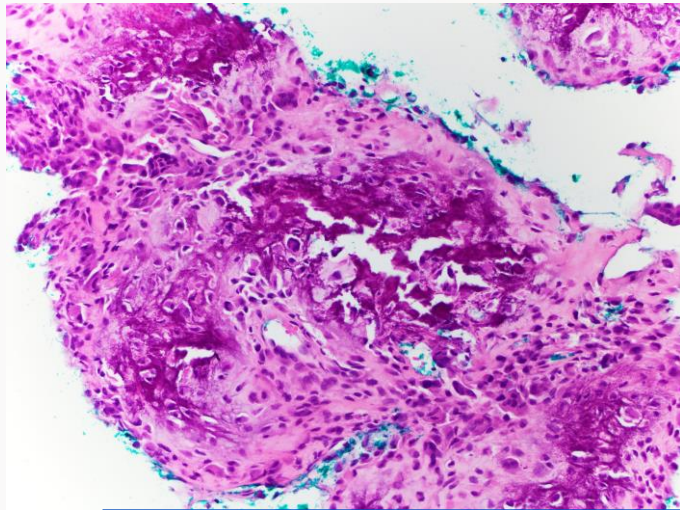
Erica Y. Kao<sup>1</sup> MD, Fisun Ardic<sup>2</sup> MD, Numrah Fadra MS<sup>3</sup>, Jessie Hohenstein PhD<sup>3</sup>, Rohini Mopuri MS<sup>3</sup>, Doris E. Wenger MD<sup>4</sup>, Lukas Streich MD<sup>5</sup>, and Andrew L. Folpe MD<sup>6</sup>

The term chondroid tenosynovial giant cell tumour is preferable to Calcified chondroid mesenchymal neoplasm , as it more accurately describes the lineage of these unusual tumours

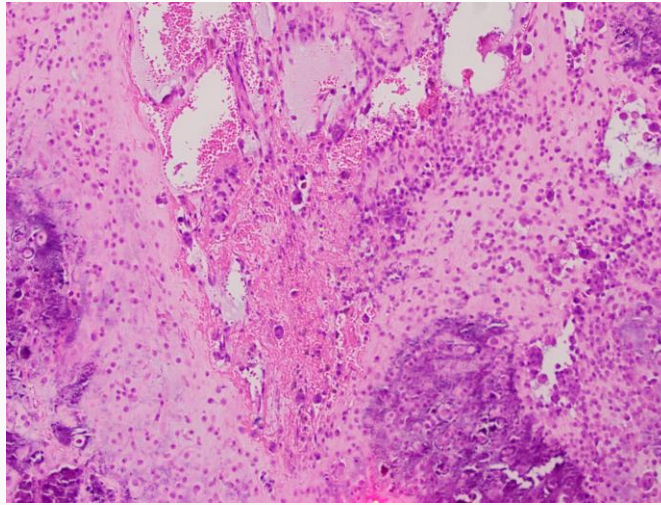
**Chondroid Tenosynovial Giant Cell Tumor:  
A Clinicopathologic, Immunohistochemical  
and Molecular Genetic Study of a Distinct  
Synoviocytic Neoplasm**

Erica Y. Kao<sup>1</sup> MD, Fisun Ardic<sup>2</sup> MD, Numrah Fadra MS<sup>3</sup>, Jessie Hohenstein PhD<sup>3</sup>, Rohini Mopuri MS<sup>3</sup>, Doris E. Wenger MD<sup>4</sup>, Lukas Streich MD<sup>5</sup>, and Andrew L. Folpe MD<sup>6</sup>

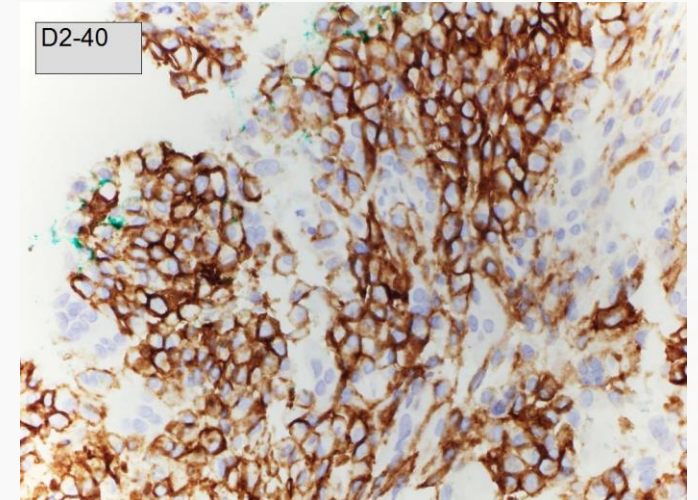
# TMJ region




Courtesy of Dr Fiona Maclean



Courtesy of Dr Alison Cheah



2001



2024



> Am J Surg Pathol. 2001 May;25(5):661-6. doi: 10.1097/0000478-200105000-00015.

## Chondroblastoma-like chondroma of soft tissue: an underrecognized variant and its differential diagnosis

J M Cates<sup>1</sup>, A E Rosenberg, J X O'Connell, G P Nielsen

## Emerging landscape of FN1-rearranged tumours

Modern Pathology (2021) 34(12):1383  
<https://doi.org/10.1038/s41375-021-00796-x>

USCAP

ARTICLE

Calcified chondroid mesenchymal neoplasms with *FN1*-receptor tyrosine kinase gene fusions including *FGFR2*, *FGFR1*, *MERTK*, *NTRK1*, and *TEK*: a molecular and clinicopathologic analysis

Yajuan J. Liu<sup>1</sup>, Wanjing Wang<sup>1</sup>, Jeffrey Yeh<sup>1</sup>, Yu Wu<sup>1</sup>, Jose G. Mendila<sup>1</sup>, Christopher D. M. Fletcher<sup>1</sup>, Robert W. Ricciotti<sup>1</sup>, Eleanor Y. Chen<sup>1</sup>

Received: 18 August 2021 / Revised: 10 February 2022 / Accepted: 13 February 2022 / Published online: 16 March 2022  
 © The Author(s), under exclusive licence to United States & Canadian Academy of Pathology 2022

Synovial chondromatosis and soft tissue chondroma: extrasosseous cartilaginous tumor defined by *FN1* gene rearrangement

Fernanda Amary<sup>1</sup>, Luis Perez-Casanova<sup>1</sup>, Hongtao Ye<sup>1</sup>, Lucia Cottone<sup>2</sup>, Anna-Christina Strobl<sup>1</sup>, Paul Cool<sup>3</sup>, Elena Miranda<sup>4</sup>, Faten Berisha<sup>5</sup>, William Aston<sup>1</sup>, Maia Rocha<sup>1,2</sup>, Paul O'Donnell<sup>1</sup>, Nischalam Pillay<sup>6,7</sup>, Roberto Tirabosco<sup>8</sup>, Daniel Baumhoer<sup>9</sup>, Edward S. Hookway<sup>9</sup>, Adrienne M. Flanagan<sup>1,2</sup>

Received: 31 March 2019 / Revised: 4 June 2019 / Accepted: 4 June 2019 / Published online: 4 July 2019  
 © The Author(s), under exclusive licence to United States & Canadian Academy of Pathology 2019

Superficial acral calcified chondroid mesenchymal neoplasm harboring an *FN1*::*FGFR2* fusion and review of the literature

Isidro Machado MD, PhD<sup>1,2,3</sup>, Vasilisa Damskou MD<sup>4</sup>, Eleftherios Ioannidis BSc, MBBS, PhD<sup>5</sup>, George Jour MD<sup>6</sup>, Konstantinos Linos MD<sup>7</sup>, Natalia Georgantzoglou<sup>8</sup>, Guozhao Shen<sup>9</sup>, George Jour<sup>1</sup>, Konstantinos Linos<sup>10</sup>

A case of *FN1*-fused calcified chondroid mesenchymal neoplasm of the hand with novel *FGFR3* partner gene

Received: 31 March 2019 / Revised: 4 June 2019 / Accepted: 4 June 2019 / Published online: 4 July 2019  
 © The Author(s), under exclusive licence to United States & Canadian Academy of Pathology 2019

## Chondroid Tenosynovial Giant Cell Tumor: A Clinicopathologic, Immunohistochemical and Molecular Genetic Study of a Distinct Synoviocytic Neoplasm

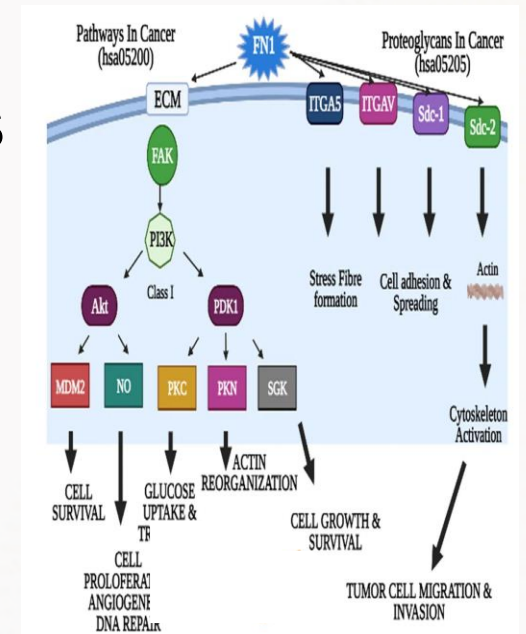
Erica Y. Kao<sup>1</sup> MD, Fisun Ardic<sup>2</sup> MD, Numrah Fadra MS<sup>3</sup>, Jessie Hohenstein PhD<sup>3</sup>, Rohini Mopuri MS<sup>3</sup>, Doris E. Wenger MD<sup>4</sup>, Lukas Streich MD<sup>5</sup>, and Andrew L. Folpe MD<sup>6</sup>

# Challenges

FN1 is a promiscuous gene

Recently reported in other mesenchymal neoplasms

- Gastrointestinal leiomyoma
- Inflammatory myofibroblastic tumor
- Lipofibromatosis
- Calcifying aponeurotic fibroma



# Take-Home Messages

- ❖ Identical gene fusion may be present in more than one phenotypically and biologically distinct neoplasm, sometimes with entirely different clinical behaviour

# Take-Home Messages

- ❖ The term CCMT is still new, controversial and evolving
- ❖ FN1 may not be the defining event for these neoplasms
- ❖ Underlying morphology, immunophenotype, clinicopathological context matters

# Calcified chondroid mesenchymal neoplasms

## – What does it mean for clinicians

- ❖ Orthopaedic surgeons have no clue what this means
- ❖ Is it malignant? Is it chondrosarcoma? Sounds like “mesenchymal chondrosarcoma”
- ❖ Recent case in our Sarcoma MDT:
  - ❖ Surgeon “What is this? What should I do with it? Is it a sarcoma?”
  - ❖ Radiologically it was typical site and appearance of a soft tissue chondroma
  - ❖ Response – “Manage as you would for a soft tissue chondroma, probably benign”
  - ❖ So then why not call it “soft tissue chondroma”

- ❖ There is an argument to split these into clinically meaningful entities...
- ❖ Future classification systems in BST neoplasms cannot be solely based on molecular events and ideally will balance morphologic features with molecular analysis

# REFERENCES

1. Liu YJ, Wang W, Yeh J, et al. Calcified chondroid mesenchymal neoplasms with FN1-receptor tyrosine kinase gene fusions including FGFR2, FGFR1, MERTK, NTRK1, and TEK: a molecular and clinicopathologic analysis. *Mod Pathol* 2021;34(7):1373–83
2. Amary F, Perez-Casanova L, Ye H, et al. Synovial chondromatosis and soft tissue chondroma: extraosseous cartilaginous tumor defined by FN1 gene rearrangement. *Mod Pathol*. 2019;32:1762–1771
3. Hoch BL, Garcia RA, Smalberger GJ. Chondroid tenosynovial giant cell tumor: a clinicopathological and immunohistochemical analysis of 5 new cases. *Int J Surg Pathol*. 2011;19:180–187
4. Cates JM, Rosenberg AE, O'Connell JX, et al. Chondroblastoma- like chondroma of soft tissue: an underrecognized variant and its differential diagnosis. *Am J Surg Pathol* 2001;25(5):661
5. Erica Y. Kao, Eleanor Y. Chen. Calcified Chondroid Mesenchymal Neoplasms. *Surgical Pathology clinic* 17 (2024) 77–82

## Acknowledgements to DHM Bone & Soft tissue pathology team:

- ❖ Drs Fiona Bonar, Fiona Maclean, Alison Cheah, Cristina Vargas, Martin Jones
- ❖ Dr Pranav Dorwal (Monash Pathology)

Thank you!

---

